

This affidavit is in compliance with article 3737e, section 7 of Vernon's Annotated Civil Statutes.

Case No. 1743-82-0902

Office of the Medical Examiner

In the matter of

In the County of DALLAS,

Raylene RICE, deceased

State of TEXAS

AFFIDAVIT

Before me, the undersigned authority, personally appeared Betty J. Lones
- - -, who, being by me duly sworn, deposed as follows:

My name is Betty J. Lones, I am over 21 years of age, of sound mind, capable of making this affidavit, and personally acquainted with the facts herein stated:


I am the Deputy Custodian of Records of the Dallas County Medical Examiner's Office. Attached hereto are 6 pages of records and xx photographs from the Dallas County Medical Examiner's Office. These said 6 pages of records and xx photographs are kept by the Dallas County Medical Examiner's Office in the regular course of business, and it was the regular course of business in the Dallas County Medical Examiner's Office for an employee or representative, or a doctor permitted to practice in the Dallas County Medical Examiner's Office, with personal knowledge of the act, event, or condition recorded to make the memorandum or record or to transmit information thereof to be included in such memorandum or record; and the memorandum or record was made at or near the time of the act, event, or condition recorded or reasonably soon thereafter. The records attached hereto are exact duplicates of the original, and it is a rule of the Dallas County Medical Examiner's Office to not permit the original to leave the Office.

Betty J. Lones
Affiant

SWORN TO AND SUBSCRIBED before me on the 9th day of August, 1982.

Louette Strange
Notary Public in and for DALLAS County, Texas

My commission expires 2/19/86



**THE SOUTHWESTERN INSTITUTE OF FORENSIC SCIENCES
AT DALLAS**

AUTOPSY REPORT
COPY

Case No. 1743-82-0902

Name: Rice, Raylene Age: 17 Race: White Sex: Female

Date and time of death: July 14, 1982 Date and time of autopsy: July 15, 1982
7:00 P.M. 3:30 P.M.

Pronounced at: Speegle Park, Hiway 6
McLennan County

Organ weights:

Brain	_____	1490	_____	Gm.
Heart	_____	280	_____	Gm.
R. Lung	_____	420	_____	Gm.
L. Lung	_____	230	_____	Gm.
Liver	_____	1010	_____	Gm.
Spleen	_____	110	_____	Gm.
R. Kidney	_____	60	_____	Gm.
L. Kidney	_____	100	_____	Gm.
_____	_____		_____	Gm.
_____	_____		_____	Gm.
_____	_____		_____	Gm.
_____	_____		_____	Gm.

EXTERNAL EXAMINATION:

Clothing on body: None.

Accompanying body:

1. Order for autopsy from Joe N. Johnson, J.P., Precinct 1, Place 2, McLennan, Texas.
2. Black disaster pouch containing ants, maggots up to 1/8 inch in length, dried grasses and weeds and pill bugs.
3. Red and white striped bra-type tank top tied over mouth as gag.
4. Beige and medium brown terry cloth strip below red and white material used as gag.
5. Strips of beige, medium brown, and rust colored material looped twice around right wrist, tied in a "Granny knot", then tied to a similar loop tied holding the hands in place behind the body.
6. White, size 38 brassiere hooked around right ankle and tied in knots with the remaining portion of the brassiere cut vertically.
7. Yellow metal, dangling earrings.
8. Yellow metal chain.
9. Two yellow metal bracelets on right wrist (below the previously described bindings).

Decomposed = D
Estimated = E
Embalmed = B
Fixed = F
Not weighed = NW

The body is that of a normally developed, normally nourished white female whose appearance is consistent with her stated age of 17 years. The body is of average build, 64-1/2 inches in length (163.8 cm.) and weighs 126 pounds (57.2 kg.). Rigor mortis is complete, livor mortis is purple and posterior. The body is cool after refrigeration and fairly well preserved in the absence of embalming.

Name Rice, Raylene

Case No. 1743-82-0902

Scalp hair is pale blonde with approximately 1/4 inch dark roots. The facial hair is not prominent. The eyes are made-up and are closed. The irides are blue-grey. The pupils are round, equal, and 6 mm. in diameter. The left ear is doubly pierced, the right singly pierced, they are otherwise unremarkable as are the nose and mouth. The teeth are natural and in good repair with orthodontic appliances in the upper and lower jaws. The neck, trunk, and extremities have no significant abnormalities. Maroon opalescent enamel is present on the toenails. The genitalia are those of an adult female and are unremarkable, except as described below. Body hair is of sparse to average amount and female distribution. No significant scars or marks are present.

EVIDENCE OF INJURY:

1. Stab wounds of neck and left chest. The wounds are consistent with a single edged blade approximately 1/2 inch in width, 1/16 inch in thickness, and between 4 and 5 inches in length. The wounds are numbered for purposes of description.

Wound No. 1 is in the midline of the neck, approximately 11 inches below the top of the head and extends 3/4 inch in a horizontal position. The blunt margin is at three o'clock. After perforating the skin and subcutaneous tissue, the blade cut the strap muscles on the left at the level of the upper pole of the thyroid, perforated the left piriform sinus. An additional track extends posteriorly through the C₆₋₇ disk to within 1/16 inch of the posterior surface of the vertebra. Epidural hemorrhage is associated with this passage of the blade as well as scant subdural and subarachnoid hemorrhage which extends to the base of the brain. No significant spinal cord injury is associated. The blade passed at least twice and passed from front to back, in one pass horizontally and slightly from left to right, in the other from below to above and approximately parallel to the midline.

Wounds No. 2 through 11 are penetrating wounds of the left chest. They are located between 13-1/2 and 17 inches below the top of the head and between 1-1/2 and 4-1/2 inches to the left of the midline. They measure 1/2 inch in length and are approximately vertically oriented with blunt margins superior.

Perforating and penetrating wounds are present as follows: left upper lobe of lung, 7; left lower lobe, 1; left ventricle of heart, 4 (3/8 to 1-1/2 inches in length); and multiple in the pericardial sac. Hemorrhage is associated with these injuries, including left hemothorax measuring 1000 cc. and hemopericardium measuring 60 cc. The overall direction of the instrument is from front to back, from above downward, and slightly from left to right.

2. Genitalia. Ant abrasion is prominent on the right thigh and the right labia majora as well as the labia minora. The anterior wall of the vagina is contused over an area 1-1/2 by 1-1/2 inches and a cervical contusion measures 1/2 by 1/4 inch anteriorly. An additional 1/2 inch

Name Rice, Raylene

Case No. 1743-82-0902

contusion is present on the cervix at three o'clock. The genitalia are otherwise unremarkable with greyish secretions present in the vagina and slightly modified by bloody secretions exuding from the cervical orifice. A rape kit is obtained and said to be negative.

3. The lips are slightly contused beneath the previously described gag consisting of red and white tank top and strips of terry cloth.

4. Minimal changes are present beneath the bonds of the arms, other than interference with ant artifact.

5. Postmortem interval. Rigor mortis remains, greenish discoloration is present in the right lower quadrant of the abdomen. Internal examination reveals moderate hemolytic changes in the intima of the blood vessels and in the serosal surfaces. The internal organs are softened, those particularly softened include the adrenal glands, pancreas, spleen, and kidneys.

6. Animal artifact. A few maggots are present within several of the wounds. Numerous ant abrasions from 1/16 inch to confluent are present over the trunk and extremities.

EVIDENCE OF MEDICAL ATTENTION: None.

INTERNAL EXAMINATION:

HEAD: Other than the focal subarachnoid hemorrhage associated with the neck wound, the scalp, skull, brain and its coverings have no evidence of preexisting disease or injury. Multiple coronal sections of the brain are unremarkable.

NECK: Other than the stab wounds described, there is no additional contusion or hemorrhage in the soft tissue of the neck or strap muscles. The hyoid bone and laryngeal cartilages are intact. The upper airways contain frothy, slightly hemorrhagic secretions. The proximal esophagus and paravertebral soft tissues are unremarkable, except for the injuries described above.

SEROUS CAVITIES: Other than the injuries described, the pleural, pericardial and peritoneal cavities contain no abnormal accumulations of fluid and the surfaces are smooth and glistening.

CARDIOVASCULAR SYSTEM: Other than the injuries described, the epicardial surface is unremarkable. The coronary arteries have balanced distribution with no atherosclerotic narrowing. The myocardium is brown with no focal lesions and the free walls measure 2 and 9 mm., right and left respectively. The posterior papillary muscle of the left ventricle is replaced by a yellow, firm tumor measuring 4.5 by 2.5 by 1.5 cm. overall. It arises from the posterior wall of the left ventricle and is fairly

Name Rice, Raylene

Case No. 1743-82-0902

clearly demarcated from the underlying red-brown myocardium. Portions of the tips of the papillary muscles remain as red-brown myocardium. The surface of the tumor is slightly lobulated, but otherwise resembles a papillary muscle configuration. No significant jet lesions are present in either the left atrium or the left ventricle. The mitral and aortic valves are unremarkable as are the remaining cardiac valves. The intimal surface of the aorta is focally roughened by fatty streaks and is discolored as described under injury. The remainder of the vascular system is unremarkable, except for the previously described hemolytic discoloration.

RESPIRATORY SYSTEM: The pleural surfaces of the right lung are dark red, those of the left are pink-grey. The right lung is subcrepitant to palpation, the left crepitant and both are soft on section. The cut surfaces of the right lung are dark red with hemorrhagic pulmonary edema exuding from the cut surfaces and those of the left are pink-grey with hemorrhage associated with the previously described defects, but are otherwise unremarkable. The distal airways contain scant, frothy secretions. The pulmonary vessels are unremarkable.

GASTROINTESTINAL SYSTEM: The distal esophagus is unremarkable. The stomach contains approximately 300 cc. of pale yellow, mostly digested food, including recognizable fragments of pimento and green pepper. The mucosa is unremarkable, as is the remainder of the digestive tract. The appendix is present.

HEPATOBIILIARY SYSTEM: The liver is tan-brown, and the hepatic architecture is unremarkable. The gallbladder contains 10 cc. of dark yellow bile.

LYMPHORETICULAR SYSTEM: The spleen is medium red and very soft. The thymus has the usual lobulated architecture. The visualized lymph nodes are unremarkable.

GENITOURINARY SYSTEM: The kidney surfaces are pale, mottled red and tan, smooth and glistening. The kidneys are soft and the cut surfaces are unremarkable, as are the collecting systems, ureters, and bladder which contains a few drops of urine. The ovaries measure approximately 4 by 2 by 1 cm. and have the usual involuting corpus lutea. The Fallopian tubes have no significant abnormalities. The uterus measures 7 by 5 by 2 cm. and the endometrium is congested to hemorrhagic. The cervical os measures 5 mm. The cervix and vagina are unremarkable, except for the previously described contusions.

ENDOCRINE SYSTEM: Other than autolysis of adrenal glands and pancreas, no abnormalities are present in the pituitary, thyroid, and adrenal glands. The pancreas is unremarkable.

MUSCULOSKELETAL SYSTEM: No fractures of the axial or appendicular skeleton are identified. The skeletal muscles are unremarkable.

Name Rice, Raylene

Case No. 1743-82-0902

HEART: Myocardial interstitial fibrosis of septum, slight. Fatty infiltration replacement of left ventricular myocardium at posterior papillary muscle with myofibrillar degeneration with fibrosis.

LUNG: Stab wound with hemorrhage. Atelectasis. Autolysis.

UTERUS: Basilar endometrium with autolysis of overlying endometrium.

CERVIX: Mucosal hemorrhage, submucosal congestion.

TOXICOLOGY:

Blood: Alcohol - 0.045% ethyl alcohol.
ABN drug screen - negative.
Alkaline drug screen - negative.
Type - 'O'.
Narcotics - negative by RIA.

Vitreous: Alcohol - negative.
SMA - Na+ - 133 meq/L.
K+ - 22 meq/L.
Cl- - 114 meq/L.
Glu - 3 mg%.
VUN - 14 mg%.

Bile: Alcohol - 0.140% ethyl alcohol.

COPY

Name Rice, Raylene

Case No. 1743-82-0902

FINDINGS:

1. Multiple stab wounds of neck and left chest with:
 - a. Wound No. 1 of neck, penetrating C₆₋₇ intervertebral disk with soft tissue, epidural, and subarachnoid hemorrhage as well as left lateral neck soft tissue hemorrhage but no defects to the great vessels.
 - b. Ten penetrating stab wounds of the left chest with perforating and penetrating wounds of the left lung, pericardium, and heart, with left hemothorax and hemopericardium as well as hemomediastinum and with an overall direction from front to back, from above downward, and from left slightly to right.
2. Blunt impact to genitalia with contusions of anterior vagina and of cervix.
3. Contusions of lips associated with gag consisting of red and white tank-top and strips of terry cloth.
4. Minimal impressions on arms and focal impression on right leg of bonds consisting of terry cloth strips on the wrists and brassiere hooked on the right ankle.
5. No other defense or scrimmage injuries.
6. Visceral pallor.
7. Early postmortem decomposition.
8. Animal artifact including small maggots and ant abrasions of trunk and extremities.
9. Endocardial and myocardial lipoma of posterior papillary muscle.

CONCLUSION:

It is our opinion that Raylene Rice, a 17-year-old white female, died as the result of multiple stab wounds of the neck and of the left chest. All of the wounds are associated with hemorrhage and were made during life. Genital injury is present with no evidence of ejaculation. The postmortem interval based on body changes and animal artifact is consistent with death late in the evening of the 13th of July, approximately 20-hours prior to discovery of the body (and that of 1741 and 1742-82) on July 14, 1982.


MANNER OF DEATH: Homicide.

TOXICOLOGY: See page 5.


COPY




M. G. F. Gilliland, M.D.
Medical Examiner



Nina Hollander, M.D.
Medical Examiner



P. E. Besant-Matthews, M.D.
Deputy Chief Medical Examiner



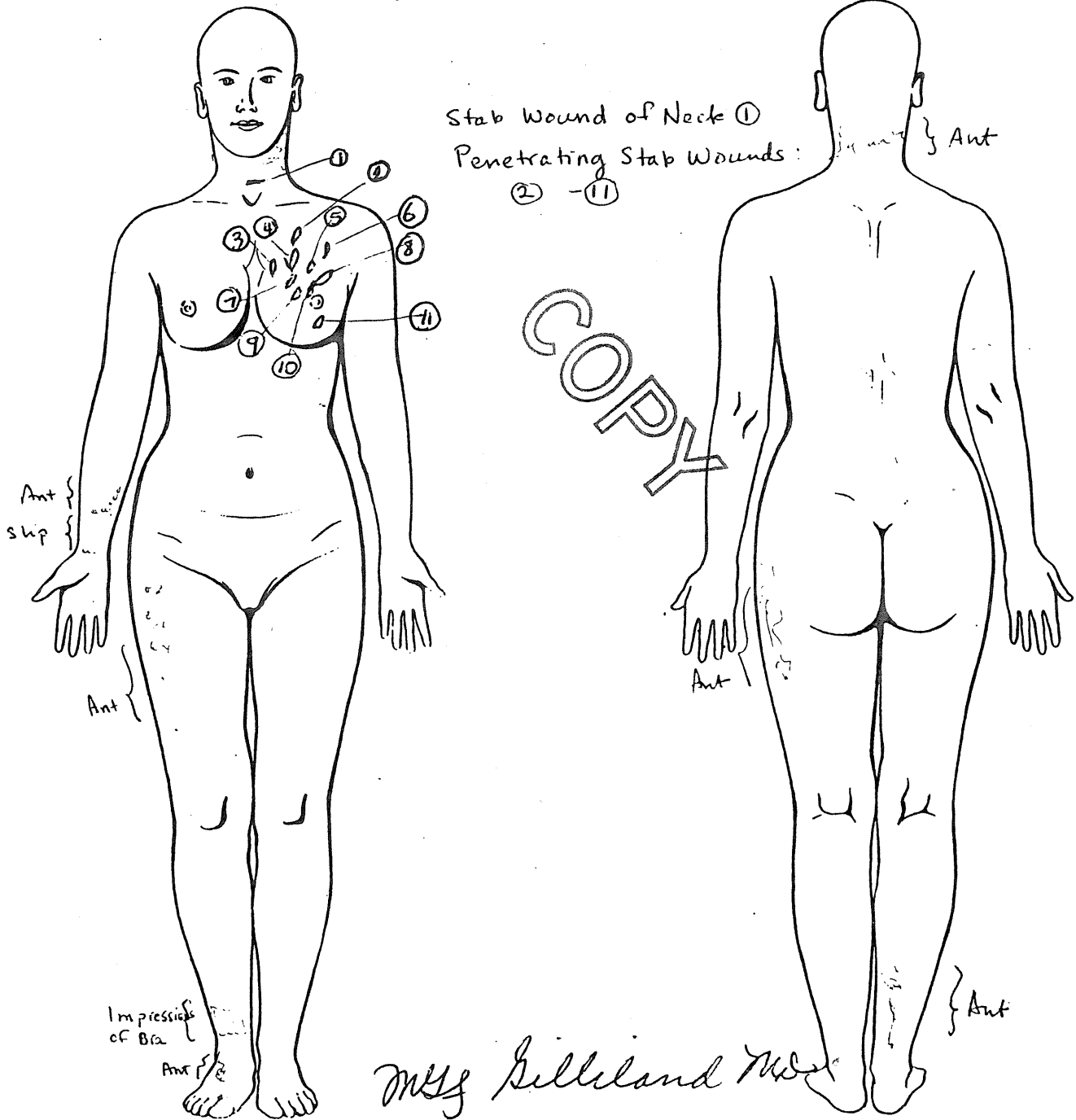
Charles S. Petty, M.D.
Chief Medical Examiner

Protocol typed by: Patricia A. Epley

THE SOUTHWESTERN INSTITUTE OF FORENSIC SCIENCES
AT DALLAS

Name Raylene Rice Autopsy No. 1743-82

Color W Age 17 Date 7/15/82



For protocol only: